

PENILE AUGMENTATION AND LENGTHENING PROCEDURE WITH PARTIAL MINIMAL INCISION

LJ Genitourinary Surgery Institute
LJ Urology Clinic

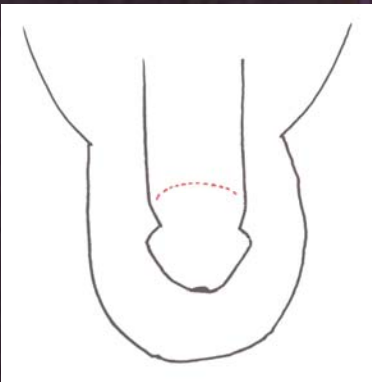
Woong Hee LEE M.D.
Su Yeon CHANG M.D.

Indications

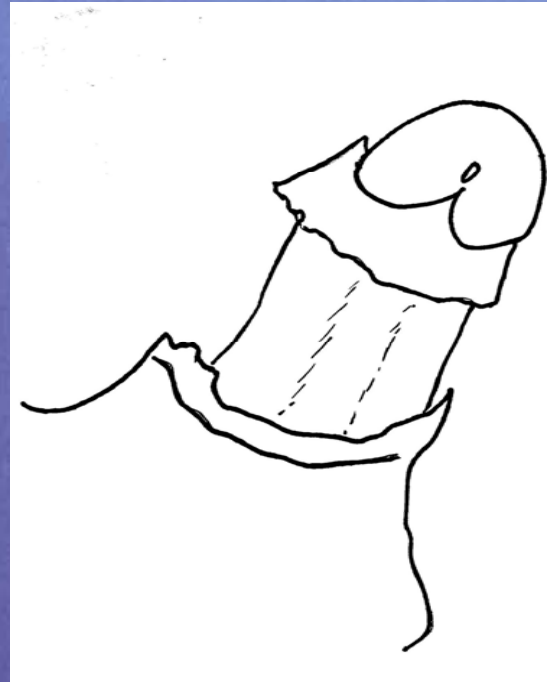
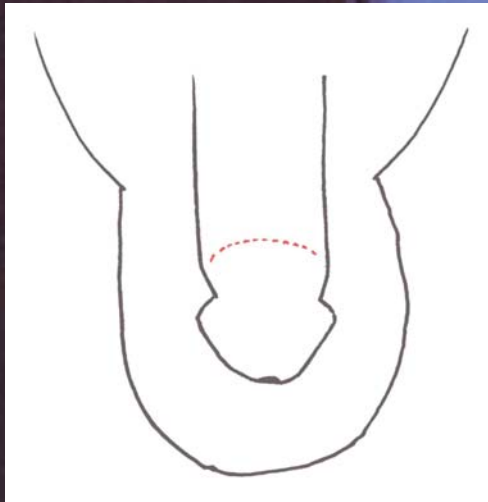
- To perform penile augmentation and lengthening procedure (PALP) for micropenis and concealed penis with partial minimal circumcision incision.
- To perform deep dissection of prepubic area during penile augmentation and lengthening procedure (PALP).
- To minimize postoperative complications such as seroma, inflammation.

Materials & Methods


- From 1999 to 2004, 145 patients underwent PALP with partial minimal incision, dorsal one third of circumcision incision.
- PALP adopted dermofat graft from gluteal region (deepithelialization).
- Graft length was 11cm and width was 4cm.



Complete circumcision incision (group 1) vs partial minimal incisions (group 2)



group 1

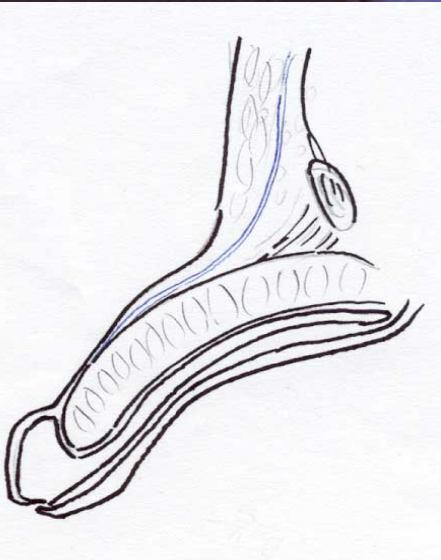


group 2

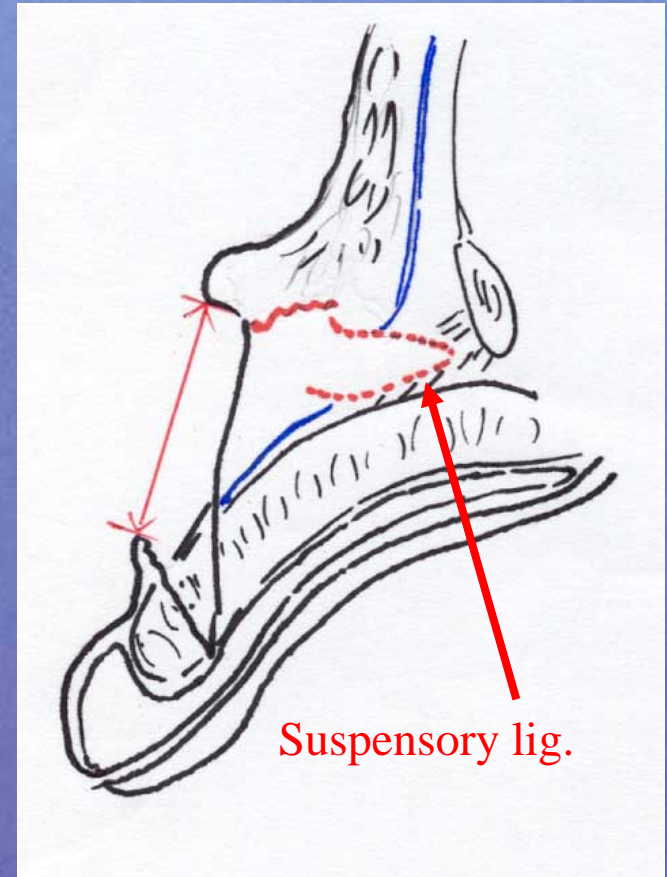
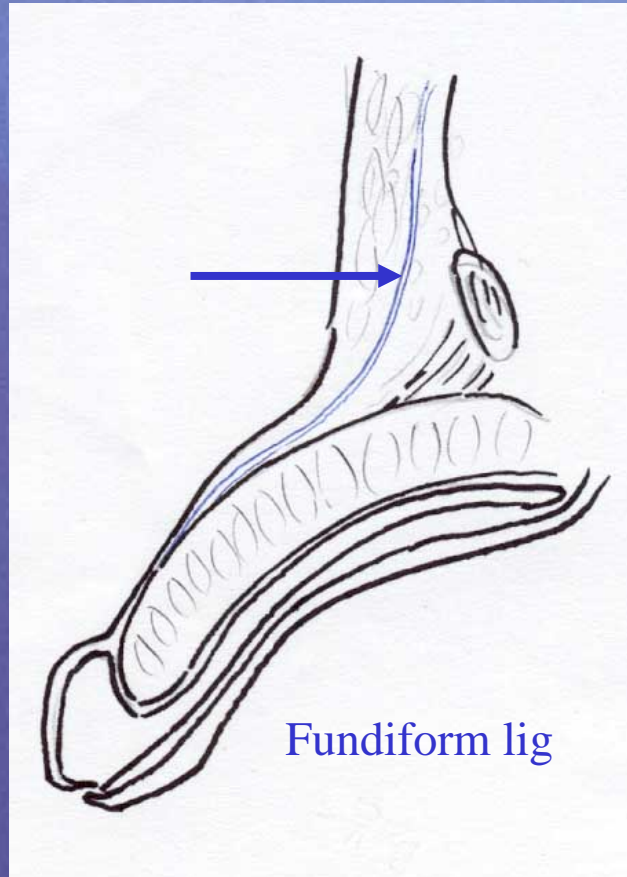
Partial Minimal incision

Materials & Methods

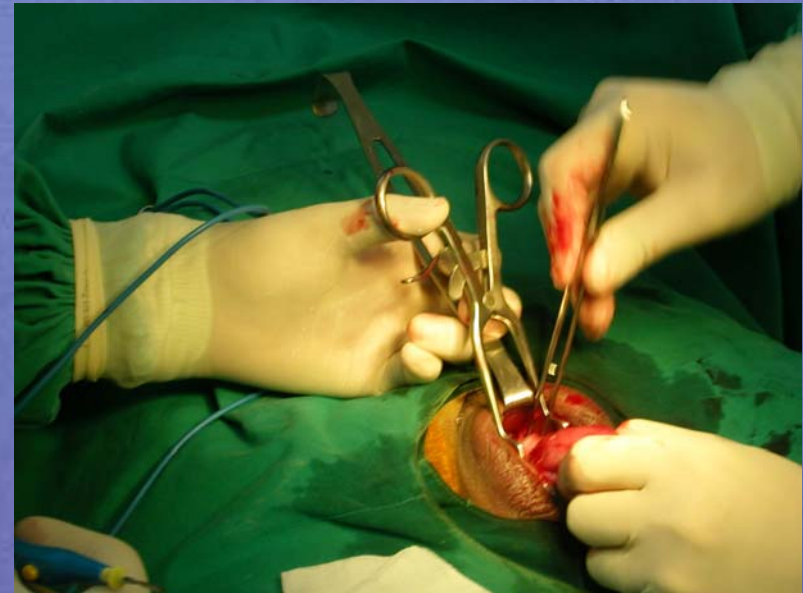
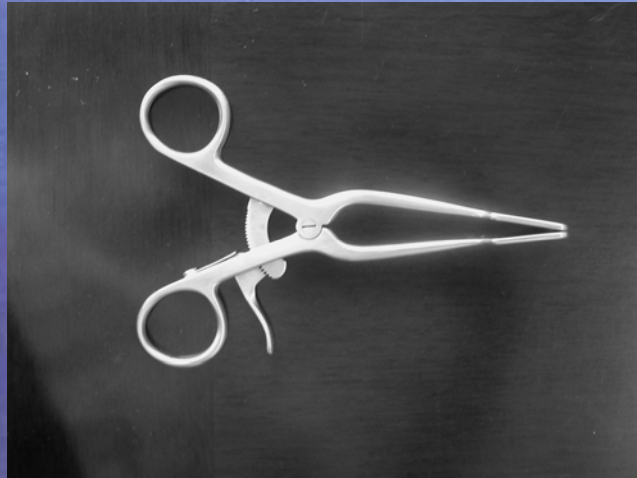
- Lengthening procedure was done with dissection of fundiform ligament and suspensory ligament.
- After dissection of ligament, multiple transverse sutures were done for approximation of prepubic dead space with absorbable sutures.



Dissection of fundiform ligament & suspensory ligament



A Novel Retractor (Lengthening Jaws)



Results

- Postoperative penile length after 3 months was 7.3 ± 1.6 cm compared with preoperative length 4.5 ± 1.2 .
- Postoperative complications were seroma and inflammatory change (3.0%).
- Graft failure was 2 cases (1.4%).

Conclusion

- For penile augmentation and lengthening procedure, partial minimal incision on circumcision incision was effective surgical procedure with minimal complications.